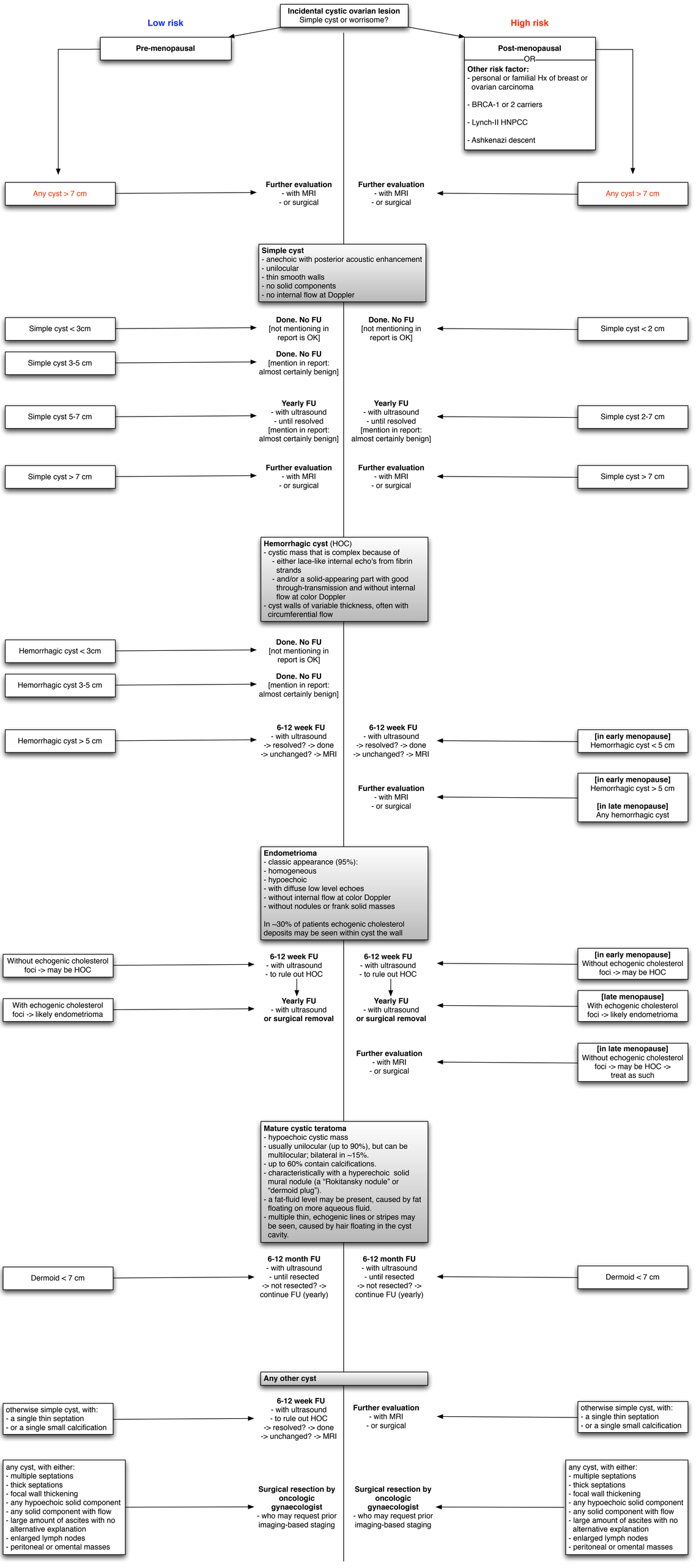
Incidental cystic ovarian lesion
Simple cyst or worrisome?
Low risk
High risk
Pre-menopausal
Post-menopausal
—OR—
Other risk factor:
- personal or familial Hx of breast or ovarian carcinoma
- BRCA-1 or 2 carriers
- Lynch-II HNPCC
- Ashkenazi descent
Any cyst > 7 cm
Further evaluation
- with MRI
- or surgical
Further evaluation
- with MRI
- or surgical
Any cyst > 7 cm
Simple cyst
- anechoic with posterior acoustic enhancement
- unilocular
- thin smooth walls
- no solid components
- no internal flow at Doppler
Simple cyst < 3cm
Done. No FU
[not mentioning in report is OK]
Done. No FU
[not mentioning in report is OK]
Simple cyst < 2 cm
Simple cyst 3-5 cm
Done. No FU
[mention in report: almost certainly benign]
Simple cyst 5-7 cm
Yearly FU
- with ultrasound
- until resolved
[mention in report: almost certainly benign]
Yearly FU
- with ultrasound
- until resolved
[mention in report: almost certainly benign]
Simple cyst 2-7 cm
Simple cyst > 7 cm
Further evaluation
- with MRI
- or surgical
Further evaluation
- with MRI
- or surgical
Simple cyst > 7 cm
Hemorrhagic cyst (HOC)
- cystic mass that is complex because of
- either lace-like internal echo's from fibrin strands
- and/or a solid-appearing part with good through-transmission and without internal flow at color Doppler
- cyst walls of variable thickness, often with circumferential flow
Hemorrhagic cyst < 3cm
Done. No FU
[not mentioning in report is OK]
Hemorrhagic cyst 3-5 cm
Done. No FU
[mention in report: almost certainly benign]
Hemorrhagic cyst > 5 cm
6-12 week FU
- with ultrasound
-> resolved? -> done
-> unchanged? -> MRI
6-12 week FU
- with ultrasound
-> resolved? -> done
-> unchanged? -> MRI
[in early menopause]
Hemorrhagic cyst < 5 cm
Further evaluation
- with MRI
- or surgical
[in early menopause]
Hemorrhagic cyst > 5 cm
[in late menopause]
Any hemorrhagic cyst
Endometrioma
- classic appearance (95%):
- homogeneous
- hypoechoic
- with diffuse low level echoes
- without internal flow at color Doppler
- without nodules or frank solid masses
In ~30% of patients echogenic cholesterol deposits may be seen within cyst the wall
Without echogenic cholesterol foci -> may be HOC
6-12 week FU
- with ultrasound
- to rule out HOC
6-12 week FU
- with ultrasound
- to rule out HOC
[in early menopause]
Without echogenic cholesterol foci -> may be HOC
With echogenic cholesterol foci -> likely endometrioma
Yearly FU
- with ultrasound
or surgical removal
Yearly FU
- with ultrasound
or surgical removal
[late menopause]
With echogenic cholesterol foci -> likely endometrioma
Further evaluation
- with MRI
- or surgical
[in late menopause]
Without echogenic cholesterol foci -> may be HOC -> treat as such
Mature cystic teratoma
- hypoechoic cystic mass
- usually unilocular (up to 90%), but can be multilocular; bilateral in ~15%.
- up to 60% contain calcifications.
- characteristically with a hyperechoic solid mural nodule (a "Rokitansky nodule" or "dermoid plug").
- a fat-fluid level may be present, caused by fat floating on more aqueous fluid.
- multiple thin, echogenic lines or stripes may be seen, caused by hair floating in the cyst cavity.
Dermoid < 7 cm
6-12 month FU
- with ultrasound
- until resected
-> not resected? -> continue FU (yearly)
6-12 month FU
- with ultrasound
- until resected
-> not resected? -> continue FU (yearly)
Dermoid < 7 cm
Any other cyst
otherwise simple cyst, with:
- a single thin septation
- or a single small calcification
6-12 week FU
- with ultrasound
- to rule out HOC
-> resolved? -> done
-> unchanged? -> MRI
Further evaluation
- with MRI
- or surgical
otherwise simple cyst, with:
- a single thin septation
- or a single small calcification
any cyst, with either:
- multiple septations
- thick septations
- focal wall thickening
- any hypoechoic solid component
- any solid component with flow
- large amount of ascites with no alternative explanation
- enlarged lymph nodes
- peritoneal or omental masses
Surgical resection by oncologic gynaecologist
- who may request prior imaging-based staging
Surgical resection by oncologic gynaecologist
- who may request prior imaging-based staging
any cyst, with either:
- multiple septations
- thick septations
- focal wall thickening
- any hypoechoic solid component
- any solid component with flow
- large amount of ascites with no alternative explanation
- enlarged lymph nodes
- peritoneal or omental masses